



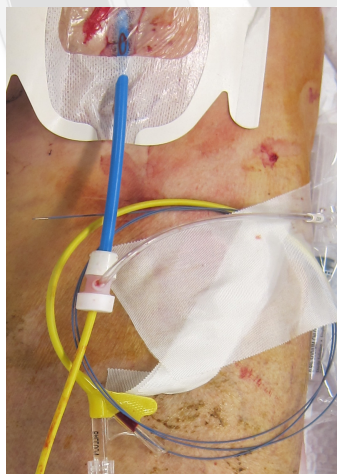
REBOA Deployed! Now what???

R. Stephen Smith MD RDMS FACS
Professor of Surgery
University of Florida
College of Medicine

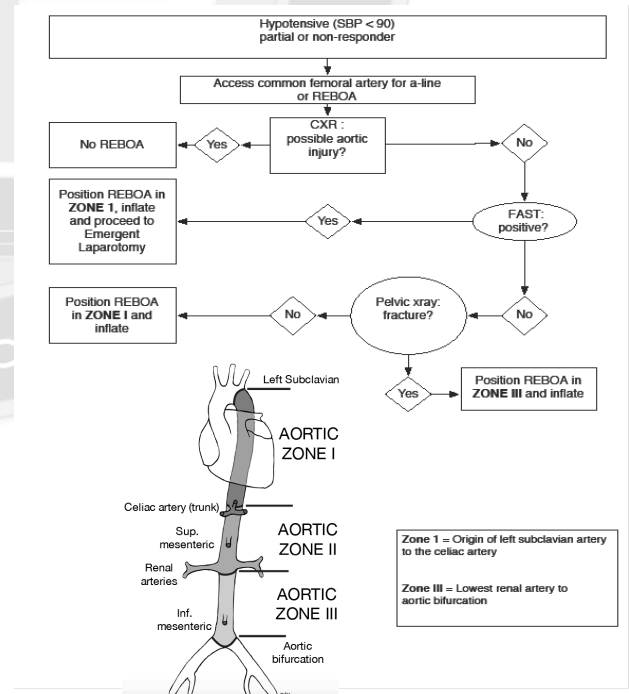
Date for publication: November 16th

The recent introduction of resuscitative endovascular balloon occlusion of the aorta (REBOA) for patients with hemorrhagic shock secondary to injuries inferior to the diaphragm is an important addition to the armamentarium of the trauma team. In early experience, outcomes with REBOA have compared favorably with resuscitative thoracotomy (RT) with aortic cross clamping in this severely injured group of patients. REBOA is not indicated in patients with hemorrhage secondary to thoracic injury, and if fact, will increase hemorrhage from injuries in the chest.

REBOA is less invasive than resuscitative thoracotomy and is performed either percutaneously or via cut down of the common femoral artery. Using the Seldinger technique, a 0.35 mm, 260 cm Amplatz guide wire is inserted via the femoral artery into the aorta (**Fig. 1**). Once proper location of the guide wire is confirmed by anatomic landmarks and/or radiographs, a 12 French introducer sheath is inserted into the aorta over the guide wire. Finally, a 9 French Coda aortic occlusion balloon is placed through the introducer sheath, over the Amplatz wire, into proper position (**Fig. 2**). If the source of hemorrhage is suspected to be in the pelvis, the balloon is inflated just superior to the aortic bifurcation (Zone III). Conversely, if the source of hemorrhage is unknown or suspected to be from intra-abdominal injury, the balloon is located and inflated at the level of the diaphragm (Zone I) (**Fig. 2**).



(Above) **Figure 1.** REBOA deployed via the left common femoral artery and secured
(Right) **Figure 2.** Algorithm and indications for REBOA.



Once REBOA has been properly deployed, an improvement of hemodynamic parameters is usually observed in patients that are not moribund. It is important to understand that improvement of the vital signs at this point in the procedure is not indicative that definitive therapy has occurred. The initial improvement of blood pressure is primarily due to an increase in afterload combined with some degree of hemostasis distal to the balloon. In effect, deployment of REBOA is “buying time” by maintaining perfusion of the brain and heart until definitive hemostasis and damage control resuscitation can be initiated. The massive transfusion protocol (MTP) should be activated in any patient in whom REBOA is performed. Following REBOA, emergency laparotomy, pelvic packing or angiographic embolization is required to provide definitive hemorrhage control.

When REBOA is performed, perfusion is maintained above the level of the balloon. Therefore, significant acidosis is certain to occur in the large tissue beds located distal to the occlusion balloon. This acidosis should be expected and preemptively treated with sodium bicarbonate and with frequent measurement of arterial blood gasses and lactic acid. The aortic occlusion balloon may be gradually deflated once the patient has been stabilized. A normal systolic blood pressure within the aorta may cause the balloon to migrate distally.

Balloon occlusion of the aorta is continued until control of hemorrhage is accomplished. Once definitive treatment of injuries has been successful, the Coda balloon and Amplatz wire should be removed. The 12 French sheath may be left in place for a period of time in the ICU until the patient is more stable. Afterwards open repair of the common femoral artery is required because of the size of the arterial defect created by the sheath. Because of the risk of arterial thrombosis or distal embolization, assessment of distal perfusion in the extremity is required and thrombectomy or embolectomy may be required to restore perfusion.

Clinical experience with REBOA is in its early phases. Ongoing trials will better define the role that this technique will play in resuscitation and treatment of patients with severe hemorrhage. Utilization of this technique is increasing and it is likely that most trauma centers will adopt this procedure in the near future. Therefore, it is important that all members of the trauma team become familiar with indications, benefits and potential complications.

References

1. Brenner ML, Moore LJ, Dubose JJ, Tyson GH, McNutt MK, Albarado RP, Holcomb JB, Scalea TM, Rasmussen TE. A clinical series of resuscitative endovascular balloon occlusion of the aorta for hemorrhage control and resuscitation. *J Trauma Acute Care Surg* 2013; 75: 505-11.
2. Rasmussen TE, Clouse WD, Peck MA, Bowser AN, Eliason JL, Cox MW, Woodward EB, Jones WT, Jenkins DH. The development and implementation of endovascular capabilities in wartime. *J Trauma* 2008; 64: 1169-1176.
3. DuBose JJ, Rajani R, Gilani R, Arthurs ZA, Morrison JJ, Clouse WD, Rasmussen TE. The endovascular skills for trauma and resuscitative surgery (ESTARS) working group. Endovascular management of axillo-subclavian arterial injury: a review of published experience. *Injury* 2012; 43: 1785-1792.
4. White JM, Cannon JW, Stnard A, Markov NP, Spencer JR, Rasmussen TE. Endovascular balloon occlusion of the aorta is superior to resuscitative thoracotomy with aortic clamping in a porcine model of hemorrhagic shock. *Surgery* 2011; 150: 400-409.
5. Morrison JJ, Percival TJ, Markov NP, Villamaria C, Scott D, Saches KA, Spencer JR, Rasmussen TE. Aortic balloon occlusion is effective in controlling pelvic hemorrhage. *J Surg Res* 2012; 177: 341-347.